

The Positive Relationship Between Excess Cement and Peri-Implant Disease: A Prospective Clinical Endoscopic Study

Thomas G. Wilson Jr.*

Background: Cement-retained restorations are commonly used on dental implants. Residual excess cement after placement of fixed partial dentures has been associated with clinical and radiographic signs of peri-implant disease. The purpose of this study was to explore the relationship between excess dental cement and peri-implant disease using the dental endoscope.

Methods: Thirty-nine consecutive patients with implants exhibiting clinical and/or radiographic signs of peri-implant disease were studied. Patients were enrolled in the study during a 5-year period in a private periodontal practice. Twelve of these patients had similar implants without signs of inflammation; these implants served as controls. There were 20 controls and 42 test implants. All were evaluated using a dental endoscope initially, and all but one implant was evaluated at a 30-day follow-up. Results from both groups were assessed by two trained operators and recorded.

Results: None of the controls and all 42 of the test implants had clinical signs of peri-implant disease at initial treatment. Excess cement was found in none of the controls and 34 of the test sites. Thirty days after cement removal, 25 of 33 test sites from which the cement was removed had no clinical or endoscopic signs of inflammation.

Conclusions: Excess dental cement was associated with signs of peri-implant disease in the majority (81%) of the cases. Clinical and endoscopic signs of peri-implant disease were absent in 74% of the test implants after the removal of excess cement. *J Periodontol* 2009;80:1388-1392.

KEY WORDS

Dental cement; dental implants; endoscope.

* Private practice, Dallas, TX.

Cemented implant prostheses have become popular as a result of their relative simplicity, elimination of prosthesis screw loosening, passivity of fit, improved esthetics, easier control of occlusion, and economy compared to screw-retained prostheses.¹ This simplicity comes with a price: the possibility of leaving excess cement on the implant or in the surrounding soft tissues,² which has been associated with peri-implant disease.^{3,4} The most likely genesis of the problem is that this cement retains microbes, similar to those responsible for inflammatory periodontal diseases, and the rough surface of the cement inhibits the removal of the microorganisms, which can lead to peri-implant disease.⁵⁻⁷

The definition of peri-implant infections is confusing. In this article, the term “peri-implant disease” is used. This has been defined as “disease that affects the tissues associated with an oral implant and/or abutment. Bacteria play a major role in the etiology of peri-implant diseases, which can be restricted to soft tissue (mucositis) or progress to the supporting bone and induce its destruction (peri-implantitis).”⁸ This study was designed to explore the relationship between retained cement, determined by dental endoscopy, and the clinical signs of peri-implant disease.

MATERIALS AND METHODS

The study was designed to identify individuals in a single private periodontal practice with clinical and/or radiographic signs of peri-implant disease. These patients were on a routine implant maintenance schedule or were referred for peri-implant evaluation and treatment. If only bleeding on probing was found, the area was debrided, and the patient was instructed to irrigate with chlorhexidine 0.12% twice daily for 30 days. If bleeding on probing was still found at reevaluation, the patient was entered into the study. Patients who presented with suppuration or clinical and/or radiographic signs of progressive bone loss were placed into the study without the initial therapy described for those with only bleeding on probing. Patients included in the study were followed prospectively ≥ 30 days subsequent to endoscopic examination and treatment where indicated. Radiographic data were used only when accurate previous films were available for comparison.

The original goal was to find 30 patients with peri-implant disease and to use implants in these same patients without signs of disease as controls. Over a 5-year period (2003 to 2008), 39 consecutive patients with 42 implants that fit the inclusion criteria were identified. The study was conducted in accordance with the Helsinki Declaration of 1975, as revised in 2000, and all patients provided oral and written consent for their therapy. All of these patients (20 females and 19 males; range, 41 to 78 years) had received dental implants with cemented single-unit fixed partial dentures. Some portions of the cement margins were located subgingivally in all of the implants. Twelve of these same patients had an additional 20 implants placed and restored under similar circumstances that showed no clinical or radiographic signs of peri-implant disease. This second group of implants served as controls.

A dental endoscope[†] was used to explore the subgingival environment around the test and control implants. Cement was identified by its characteristic white reflectance, whereas subgingival calculus was

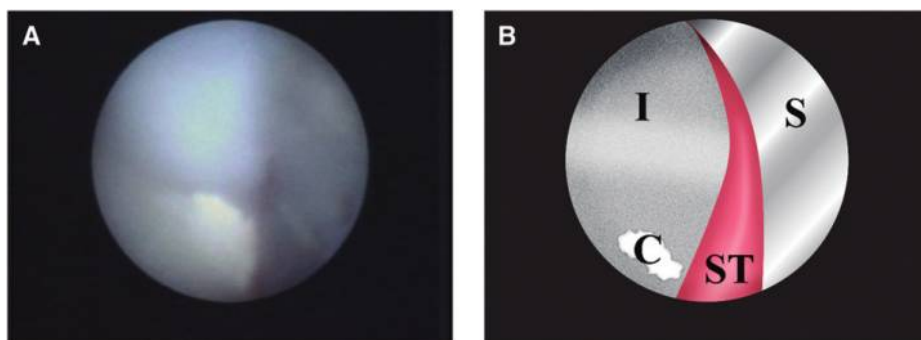


Figure 1.

A) A piece of cement, ~ 0.5 mm in diameter, attached to the implant surface is seen in the lower left quadrant of the screen grab from the endoscope. **B)** An illustration of A. I = implant; S = shield; C = cement; ST = soft tissue.

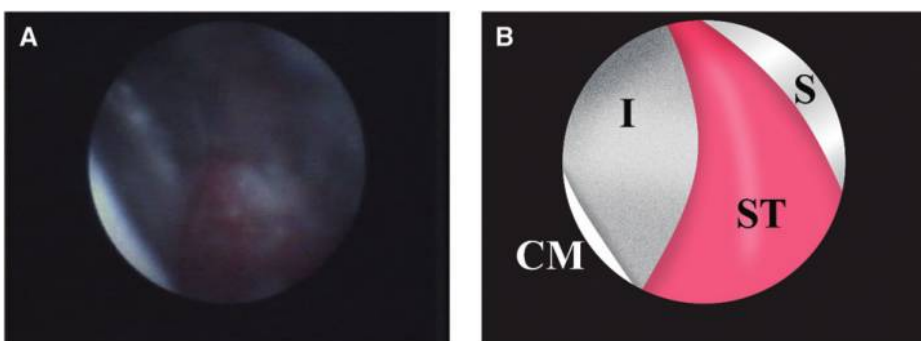


Figure 2.

A) An endoscopic view of the same implant seen in Figure 1 after cement removal. **B)** An illustration of A. I = implant; S = shield; CM = crown margin; ST = soft tissue.

brown or yellow. A material assumed to be biofilm was gray/blue. Biofilm can be easily dislodged with the endoscope's explorer, whereas cement and calculus cannot. The subgingival deposits can be more readily identified using the moving images seen when the endoscope is used in a clinical setting compared to static screen grabs (Figs. 1 and 2). The device was used by individuals trained and experienced in its use. At least two individuals, the periodontist and a dental hygienist, confirmed the presence or absence of cement. If excess cement was found, its presence was recorded, and its removal was attempted using varied hand scalers as well as piezoelectric and magnetostrictive mechanical devices while visualizing the cement with the dental endoscope. In three cases, a flap approach was necessary to accomplish cement removal.

The restorative dentist who cemented the restoration was contacted, and information on the type of cement used was recorded. This information was

[†] DentalView, Irvine, CA.

available for 39 of 42 test implants. Sixty of the implants had titanium plasma-sprayed or sand-blasted large-grit acid-etched surfaces. Two had titanium grit (titanium dioxide)-blasted surfaces.

Forty-one of 42 implants with peri-implant disease were reevaluated by the initial examiners clinically and with an endoscope ~1 month after therapy. One patient dropped out before a follow-up evaluation could be performed.

RESULTS

Cement was associated with 34 of 42 test implants (80.95%) and no control implants (0%). Of the 33 test implants available for evaluation at the 1-month interval, the clinical and endoscopic signs of peri-implant disease had resolved in 25 implants. No signs of peri-implant disease were seen around the control implants, on clinical evaluation or when the sulcus was observed with the endoscope. The cause of the continued inflammation around the remaining eight implants remained undetermined. Four types of cement were used from five manufacturers (Table 1). Within the scope of this study, no difference could be detected in the initial presence of disease or response to treatment based on the type of cement used to lute the restoration. The type of implant surface did not seem to have any effect on the presence of inflammation or the retention of cement.

Peri-implant disease was first diagnosed in the test implants loaded from 4 months to >9 years after cementation of the single-unit fixed partial dentures (Fig. 3).

DISCUSSION

The majority of the tissues surrounding the implants (81%) in this study demonstrating signs of peri-implant disease had retained excess cement in the subgingival spaces. Additionally, the removal of the excess cement with a closed procedure using the dental endoscope or, when necessary, a surgical flap procedure eliminated signs of inflammation after 1 month in most (25 of 33) of the treated implants. This

Table 1.

Type of Cement and Number of Implants

Type of Cement	Test Implants (n)
Resin modified glass ionomer (two manufacturers)	27
Zinc polycarboxylate	7
Resin cement	4
Glass ionomer	1

There was no apparent relationship between the type of cement used and the presence of peri-implant disease. Information on the type of cement used was not available for three of the test implants.

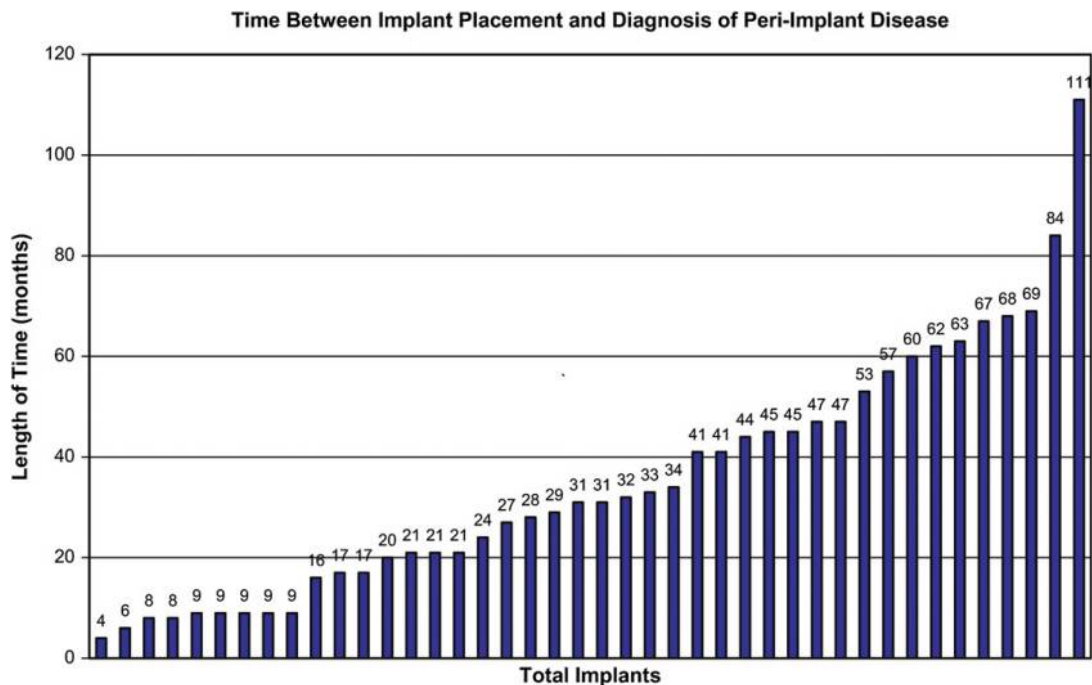


Figure 3.

The presence of peri-implant disease was discovered as soon as 4 months after cementing the fixed partial denture and as long as 111 months. Each bar represents an individual implant.

seemed to indicate that retained cement, where present, may be a major contributor to peri-implant disease.

It is remarkable that the initial signs of inflammation and peri-implant disease were found from as early as 4 months to >9 years after fixed-implant restorations were cemented. This agrees with the findings of Pauletto et al.,³ who found manifestations of peri-implant disease from a few weeks to 4 years after cementation. This delayed response cannot be fully explained, but the roughness of deposits on natural root surfaces has long been associated with periodontal inflammation; the removal of root roughness is associated with resolution of inflammation.⁸ The existence of even a tiny amount of calculus was associated with inflammation of the pocket wall around natural teeth, and removal of this roughness was associated with the resolution of the endoscopic signs of inflammation.⁹⁻¹¹ Dental cement on implants may serve the same function. Bacteria from the implant sulcus were shown to be capable of causing peri-implant disease.⁶ In the current study, removal of cement frequently (76% of the time) resulted in resolution of the clinical and endoscopic signs usually associated with peri-implant disease. It is not known if this is due to the removal of a mechanical irritant or a repository of bacteria or both. Clinically, it seems that both are important.

Based on this study, it seems that removal of excess cement from around implants is important for retaining clinical health and for the resolution of peri-implant disease. In most cases, by using the dental endoscope, the cement could be visualized and removed using a non-surgical procedure. However, in three cases, surgical access was necessary for complete cement removal. It seems that excess cement found in the presence of peri-implant disease should be removed by whatever methods are necessary; surgical intervention is justified when this cannot be accomplished with non-surgical approaches.

CONCLUSIONS

If these findings are confirmed by other studies, they argue for increased diligence in cement removal at the time of cementation, as well as arousing suspicion of excess cement when signs of peri-implant disease are seen. The need for care in the use of cemented restorations needs to be communicated to the restorative dentist, and it emphasizes the need for cooperation during treatment planning between the surgeon and restorative dentist. Screw-retained fixed partial dentures may be indicated in situations where cement margins will be located under the gingiva and cement removal will be problematic. When cementation is

to be used, alternative approaches can include abutments that raise the crown/abutment margin coronally or abutments offset internally in relation to the coronal margin of the implant shoulder. In all cemented cases, due diligence should be paid to removing all excess cement at the time of placement of the fixed partial denture. The delay in the appearance of peri-implant disease is particularly troubling and indicates that cemented implant prostheses should be evaluated periodically for peri-implant disease.

ACKNOWLEDGMENTS

The author thanks Dr. Steve Harrel, private practice, Dallas, Texas, and clinical professor, Baylor College of Dentistry, Dallas, Texas, for his review of this article. The author thanks Kara Webb, registered dental hygienist, private practice, Dallas, Texas, for her help in the clinical aspects and Ms. Lauren Ardoin, registered dental assistant, Dallas, Texas, for her help in manuscript preparation. This article was written and funded solely by the author. The author reports no conflicts of interest related to this study.

REFERENCES

1. Squier RS, Agar JR, Duncan JP, Taylor TD. Retentiveness of dental cements used with metallic implant components. *Int J Oral Maxillofac Implants* 2001;16:793-798.
2. Agar JR, Cameron SM, Hughbanks JC, Parker MH. Cement removal from restorations luted to titanium abutments with simulated subgingival margins. *J Prosthet Dent* 1997;78:43-47.
3. Pauletto N, Lahiffe BJ, Walton JN. Complications associated with excess cement around crowns on osseointegrated implants: A clinical report. *Int J Oral Maxillofac Implants* 1999;14:865-868.
4. Gapski R, Neugeboren N, Pomeranz AZ, Reissner MW. Endosseous implant failure influenced by crown cementation: A clinical case report. *Int J Oral Maxillofac Implants* 2008;23:943-946.
5. Pontoriero R, Tonelli MP, Carnevale G, Mombelli A, Nyman SR, Lang NP. Experimentally induced peri-implant mucositis. A clinical study in humans. *Clin Oral Implants Res* 1994;5:254-259.
6. Berglundh T, Lindhe J, Marinello C, Ericsson I, Liljenberg B. Soft tissue reaction to de novo plaque formation on implants and teeth. An experimental study in the dog. *Clin Oral Implants Res* 1992;3:1-84.
7. Lang NP, Berglundh T, Heitz-Mayfield LJ, Pjetursson BE, Salvi GE, Sanz M. Consensus statements and recommended clinical procedures regarding implant survival and complications. *Int J Oral Maxillofac Implants* 2004;19(Suppl.):150-154.
8. Laney WR, ed. *Glossary of Oral and Maxillofacial Implants*. Hanover Park, IL: Quintessence Publishing; 2007:122.

9. Cobb CM. Non-surgical pocket therapy: Mechanical. *Ann Periodontol* 1996;1:443-490.
10. Wilson TG, Harrel SK, Nunn ME, Francis B, Webb K. The relationship between the presence of tooth-borne subgingival deposits and inflammation found with a dental endoscope. *J Periodontol* 2008;79:2029-2035.
11. Wilson TG Jr., Carnio J, Schenk R, Myers G. Absence of histologic signs of chronic inflammation following closed subgingival scaling and root planing using the

dental endoscope: Human biopsies – A pilot study. *J Periodontol* 2008;79:2036-2041.

Correspondence: Dr. Thomas G. Wilson Jr., 5465 Blair Rd., Suite 200, Dallas, TX 75231. Fax: 214/691-2228; e-mail: tom@tgwperio.com.

Submitted February 24, 2009; accepted for publication May 11, 2009.